

PMI Newsletter

Scientific Update 2024

- EWMA 2024 -

- » **The beneficial use of SUPRA SDRM®:**
 - » Fast healing in challenging wounds
 - » Increased angiogenic response and oxygen saturation
 - » Wound closure and limb salvage in hard-to-heal diabetic wounds

- » **The beneficial use of SUPRA THEL®:**
 - » Epithelization in patients with pyoderma gangrenosum

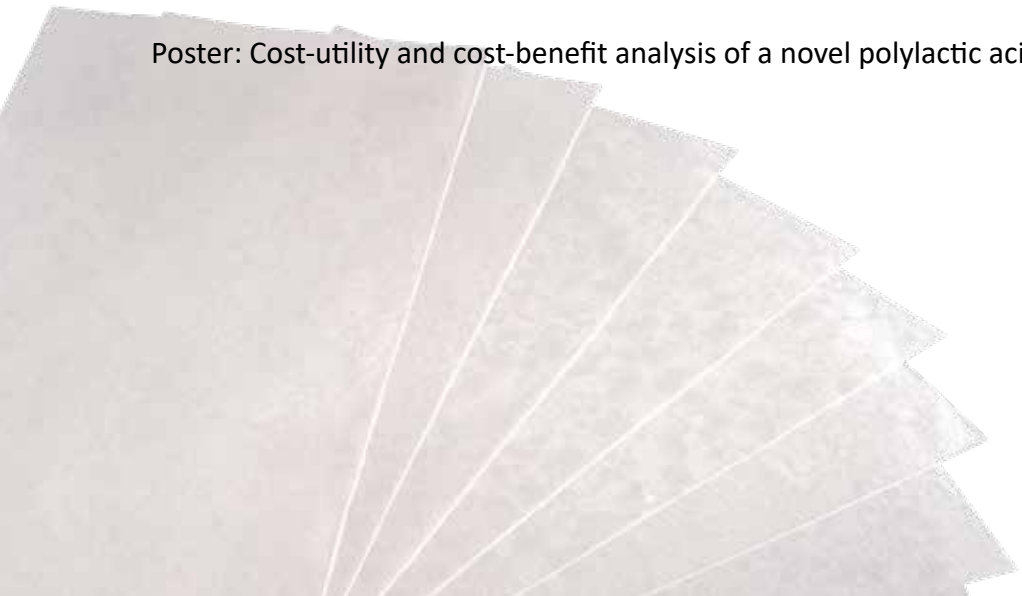
- » **Cost analysis for SUPRA SDRM®:**
 - » Total cost per patient reduced by half compared to SoC with collagen dressings



The Wound Healing Company

Table of Contents

Introduction: PolyMedics Innovations GmbH & our synthetic skin substitutes SUPRA SDRM® and SUPRATHEL®	2
Poster: Using a polylactic acid dermal matrix for achieving wound healing in challenging wounds	3-4
Poster: Assessing a wound's viability and neovascularization in real time using multispectral near-infrared imaging.....	5-6
Poster: Using a novel polylactic acid dermal matrix for achieving closure and limb salvage in hard-to-heal diabetic wounds.....	7-8
Poster: Using a polylactic acid dermal matrix for achieving wound epithelization in patients with pyoderma gangrenosum	9-10
Poster: Cost-utility and cost-benefit analysis of a novel polylactic acid dermal matrix for the closure of Diabetic Foot Ulcers.....	11



PolyMedics Innovations (PMI)

Intelligent Wound Care

Our mission is to support health care professionals by providing unique medical products that help care for patients who are suffering from hard-to-heal wounds.

Our innovations start with research collaboration with world-renowned hospitals and research institutions. Development of medical products for wound care patients worldwide is our motivation to revolutionize care.

» Our skin substitutes are biodegradable, fully synthetic and therefore pose no risk of transmitting disease or causing immunological reactions.

SUPRA SDRM[®]

Guided wound healing matrix

- » Reduces healing time – up to 44%¹
- » Reduces pH²
- » Increases neovascularization³



SUPRATHEL[®]

The temporary second skin

- » Single (one-time) application reduces workload
- » Significant pain relief¹⁻³
- » Fast wound healing^{1,4}
- » Reduced inflammatory response^{4,5}



¹ Liden and Ramirez-GarciaLuna: Wounds. 2023 Aug;35(8):E257-E260.

² Unpublished data: pH reduction in vitro with different starting pH levels of water.

³ Ring et al. 2010: Int J Artif Organs Dec;33(12):877-84 (preclinical data).

¹ Uhlig et al. 2007: Burns. 33(2):221-9.

² Schwarze et al. 2007: Burns. 33(7):850-4.

³ Schwarze et al. 2008: Ann Plast Surg. 60(2):181-5.

⁴ Gürünlüoğlu et al. 2019: J Burn Care Res, Jun 21;40(4):444-450.

⁵ Demircan et al. 2021: Ulus Travma Acil Cerrahi Derg Actions. Jan;27(1):122-131.

Poster presentation

Using a polylactic acid dermal matrix for achieving wound healing in challenging wounds

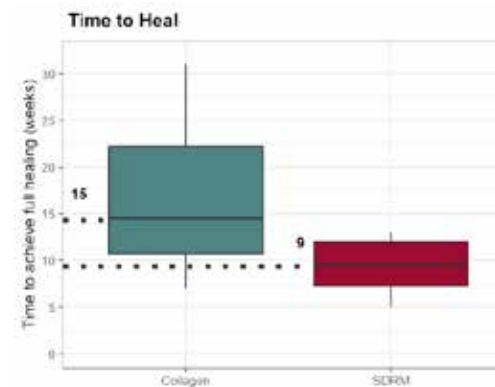
Matthew Regulski¹, Jose L. Ramirez-Garcialuna²

¹Wound Care Institute of Ocean County, NJ,USA. ²McGill University, Montreal, QC, Canada

Under ideal and controlled conditions, the polylactic acid dermal matrix SUPRA SDRM® has demonstrated a reduced healing time by 44%¹. The authors of this publication describe the release of lactate from the polylactide-containing matrix and the resulting lactate effects as the underlying mechanism, as there is a significant body of evidence that lactate has a signaling effect that triggers wound healing.

In the present cohort study with 15 patients, Dr. Regulski and Dr. Ramirez-Garcialuna sought to determine if the same effects of SUPRA SDRM® hold under “real world” conditions; particularly in challenging wounds (including diabetic foot ulcers, venous ulcers, inflammatory ulcers and trauma injuries).

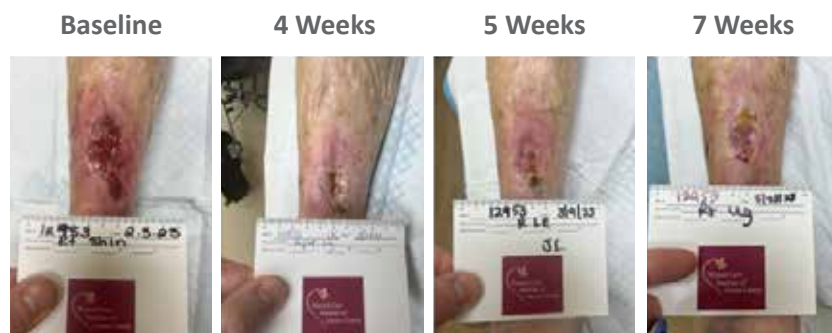- Healing improved significantly in most patients
 - » 4 wounds healed within 3 weeks
 - » 80% of the wounds healed by 12 weeks
 - » The remaining 2 wounds healed within 15 weeks.
- Repair tissue characterized by
 - » abundant granulation tissue
 - » thick epithelial borders
- Reductions in erythema on inflammatory ulcers



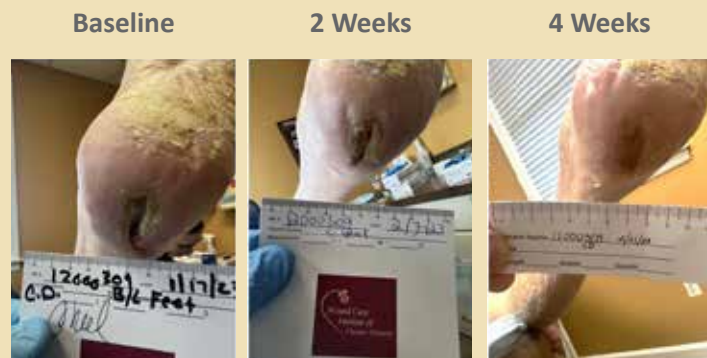
modified according to ¹ Liden and Ramirez-GarciaLuna 2023: Index Wounds. 2023;35(8):E257-E260.



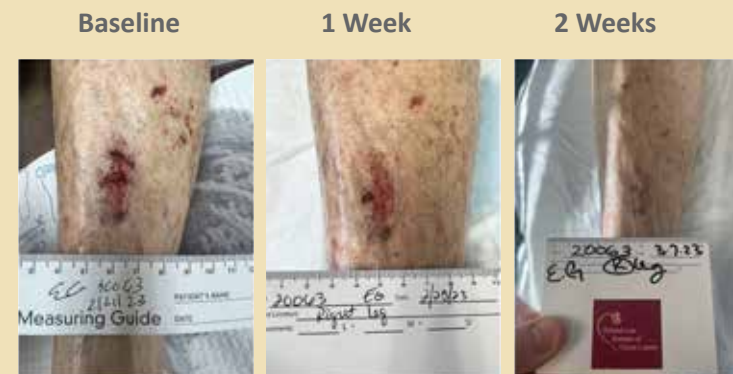Patient: 71 years, female
 Wound: Pyoderma gangrenosum, present for 2 years
 Healing time: 8 weeks (within 4 weeks the wound size reduced by over 80%)



Patient: 72 years
 Wound: Diabetic foot ulcer, present for 6 months and other treatment modalities had failed
 Healing time: 4 weeks (within 2 weeks the wound size reduced by 50%)



Patient: 89 years
 Wound: Skin tear (trauma), history of frequent skin tears that were difficult to heal
 Healing time: 2 weeks



Poster presentation

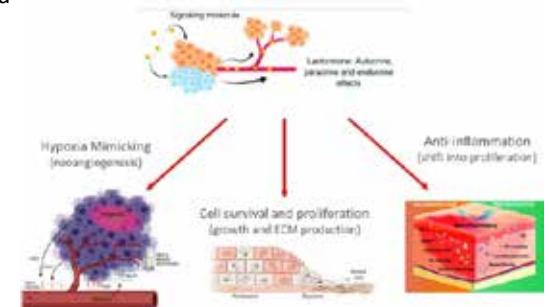
Assessing a wound's viability and neovascularization in real time using multispectral near-infrared imaging

Matthew Regulski¹, Karen Cross², Jose L. Ramirez-Garcialuna³

¹Wound Care Institute of Ocean County, NJ,USA, ²Dalhousie University, Halifax, NS, Canada. ³McGill University, Montreal, QC, Canada

It is well known that lactate has potent signaling effects that include:

- Hypoxia mimicking and triggering of neo-angiogenesis
- Cell survival and proliferation
- Anti-inflammation
- Wound pH acidification



Ring et al. 2010: Int J Artif Organs 2010; 33 (12): 877-884

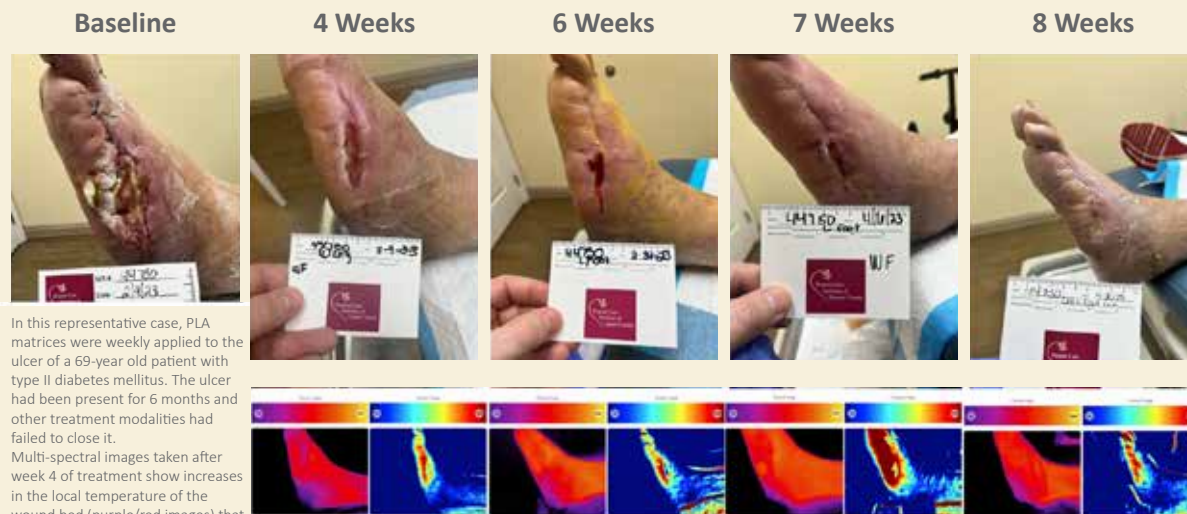
In this work Regulski et al. assessed the bed of wounds with the polylactic acid (PLA) matrix SUPRA SDRM[®] using an optical device to quantify temperature and tissue oxygenation levels.

The observations on the basis of 5 patients with chronic wounds are summarized as follows:

- Healing improved significantly in most patients
- A neoangiogenic response was induced
- ECM remodelling was promoted
- Deposition of large content of granulation tissue and the apparition of thick epithelial borders in the wound's edge
- Oxygen saturation of the wound bed increased over time
- As well as the temperature of the peri-wound area



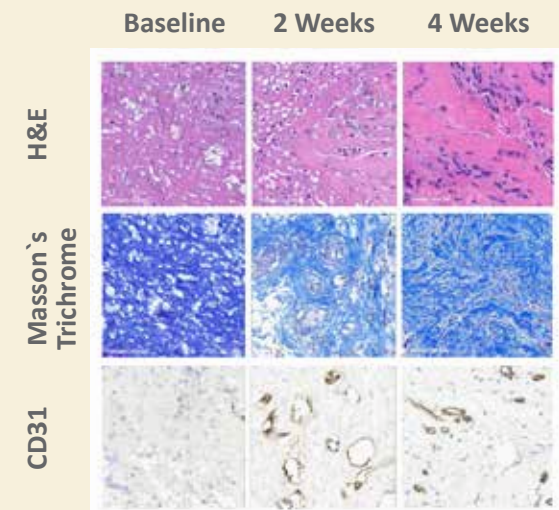
Patient: 69 years
Wound: Diabetic foot ulcer, present for 6 months and other treatment modalities had failed
Healing time: 8 weeks (within 4 weeks the wound size reduced by 60%)



In this representative case, PLA matrices were weekly applied to the ulcer of a 69-year old patient with type II diabetes mellitus. The ulcer had been present for 6 months and other treatment modalities had failed to close it. Multi-spectral images taken after week 4 of treatment show increases in the local temperature of the wound bed (purple/red images) that correlate with changes in the oxygen content of the tissue (blue/red images). As the wound heals and more granulation tissue is deposited, the multispectral image shows increases in highly oxygenated areas (red). These areas peak just before closure of the wound.

Tissue biopsy confirms that SUPRA SDRM® induces a powerful neoangiogenic response and promotes ECM remodelling of wounds

“Here, we confirm how the external administration of lactate into a wound bed leads to an increased angiogenic response that is critical for achieving healing.”



SUPRA SDRM[®]

Poster presentation

Using a novel polylactic acid dermal matrix for achieving closure and limb salvage in hard-to-heal diabetic wounds

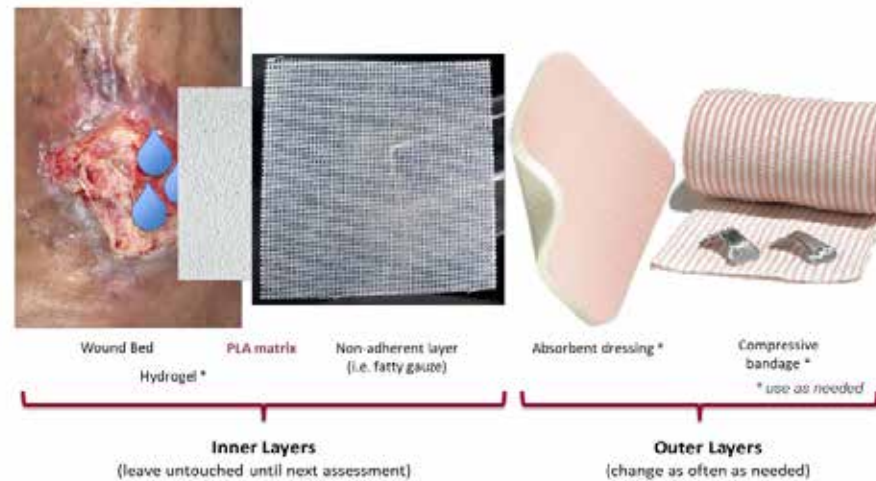
Brock Liden¹, Jose L. Ramirez-Garcialuna²

¹WAFL, Circleville, OH, USA. ²McGill University, Montreal, QC, Canada

Dr. Brock Liden, one of our the first users of SUPRA SDRM[®] in the US describes four cases of hard-to-heal wounds where SUPRA SDRM[®] matrix led to:

- restoring an appropriate healing environment
- full wound closure
- limb salvage

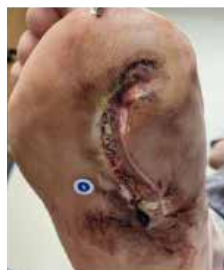Dr. Liden has established the following application scheme:



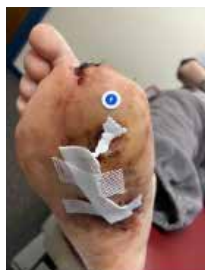

Patient: 35 years
Wound: Acute plantar wound
Comorbidities: Diabetes, obesity
Healing time: 9 weeks

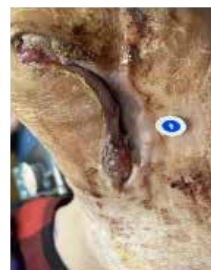Initial Presentation



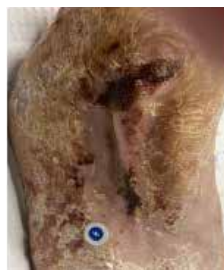Initial Presentation



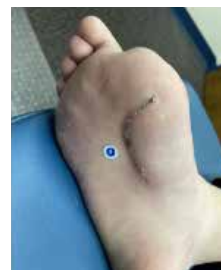Week 4



Weeks 7

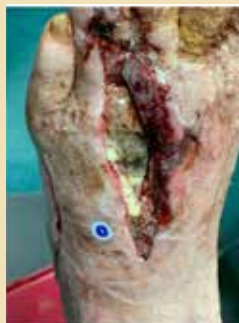

Weeks 9

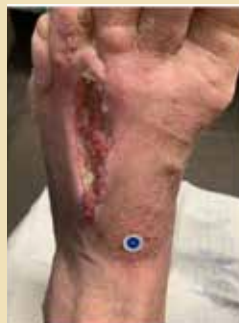

Patient: 60 years, male
Wound: Surgical wound due to abscess incision and drainage
Comorbidities: Diabetes, heart failure, peripheral arterial disease
Healing time: 12 weeks

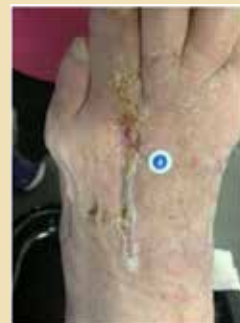Initial Presentation



Week 5

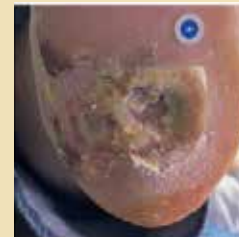

Week 12

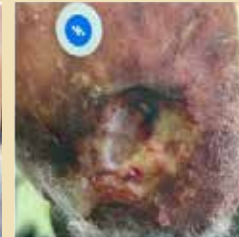


Patient: 47 years, female
Wound: Open heel ulcer, present for 2 years
Comorbidities: Osteomyelitis
Healing time: 7 weeks

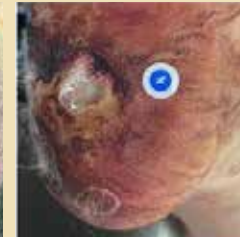
Initial



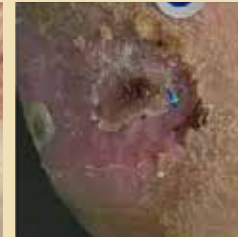Week 2



Week 5



Week 7



Poster presentation

Using a polylactic acid dermal matrix for achieving wound epithelization in patients with pyoderma gangrenosum

Mario A. Martinez-Jimenez ¹, Jose L. Ramirez-Garcialuna ²

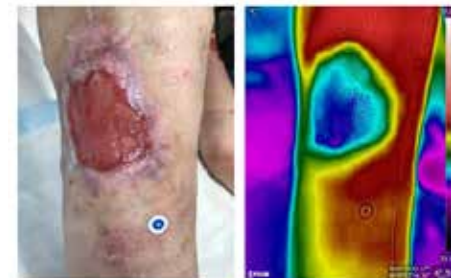¹Department of Surgery, Universidad Autonoma de San Luis Potosi, San Luis Potosi, Mexico. ²McGill University, Montreal, QC, Canada

Pyoderma gangrenosum (PG) is an inflammatory skin disease with painful ulcerative lesions. The diagnosis of PG wounds is difficult. Under infrared thermal imaging, PG wounds appear unusually cold, indicating destruction of the wound vessels and lack of blood flow.

However, Dr. Martinez-Jimenez was able to successfully treat 3 patients with PG with the PLA based synthetic skin substitute SUPRATHEL[®].

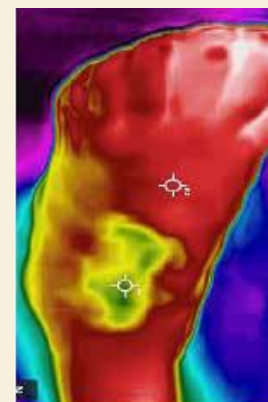
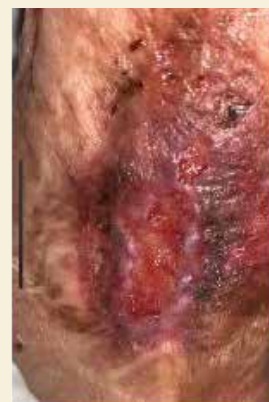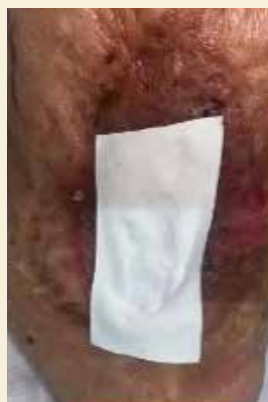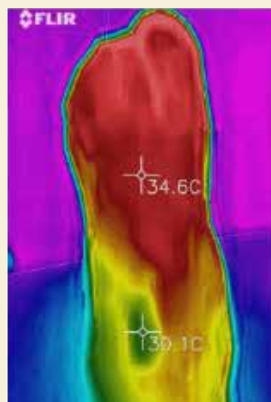
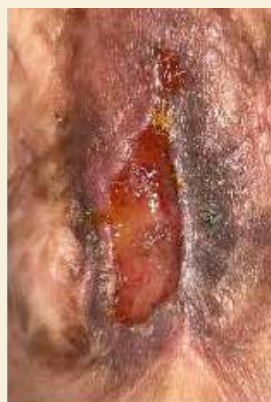Here are his cases:

- SUPRATHEL[®] was left on the wound for 2-4 weeks
 - » A longer period has proven to be beneficial
- All wounds healed after 1-5 applications of SUPRATHEL[®]
- Thermal imaging showed a significant increase in temperature in the wound area
 - » indicates improved blood flow to the wound bed



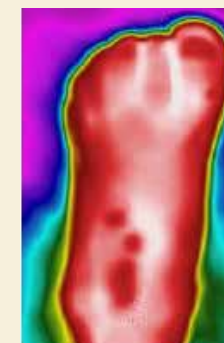
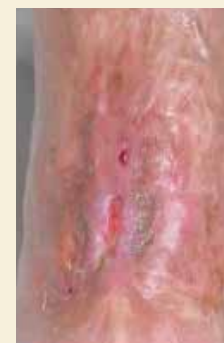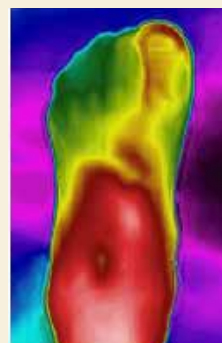

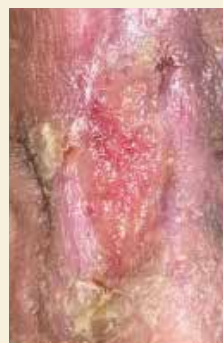
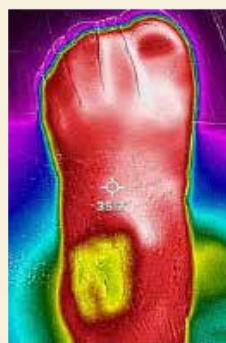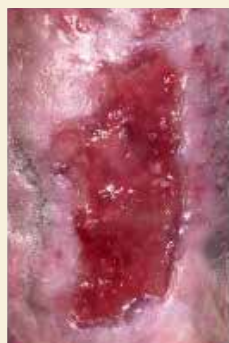Patient: 56 years, female



Initial Presentation: This wound had undergone a series of failed healing attempts, which left scarred and contracted tissue. Thermographic assessment of the wound bed showed a cold ulcer and distal hyperaemia.

Third Assessment: After the third administration of a PLA matrix, significant improvement was found. Epithelial borders and thermal changes are compatible with wound healing. The decision to leave the PLA matrices for longer periods of time was thus made.



12-Weeks: After 12-weeks of treatment and 5 rounds of PLA matrices, the wound bed has been completely filled with granulation tissue

18-weeks: After 18-weeks of treatment, the wound size has been reduced by >60% and its depth is negligible. Thermal asymmetry is <30C.

24-weeks: The wound has almost completely healed. The healing tissue looks less scarred than the previous healing attempts. The temperature distribution in the foot is almost homogeneous.

Poster presentation

Cost-utility and cost-benefit analysis of a novel polylactic acid dermal matrix for the closure of Diabetic Foot Ulcers

Elaheh Khorasani ¹ Brock Liden ², Jose L. Ramirez-Garcialuna ¹

¹ WAFL, Circleville, OH, USA. ² McGill University, Montreal, QC, Canada

A recently published randomized controlled trial showed the following benefits of SUPRA SDRM[®] in diabetic foot ulcers (DFU) compared to standard treatment (collagen dressings)¹:

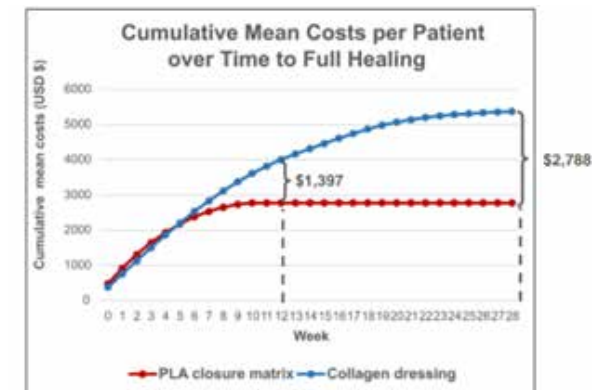
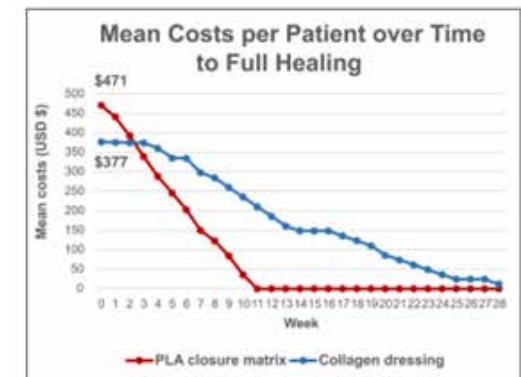
- » healing time is reduced by 44% when using SUPRA SDRM[®]
- » 90% of the SUPRA SDRM[®]-treated wounds healed by 12 weeks (vs. 30% in the SoC group)

Here the authors present a cost-utility and cost-benefit analysis of these data:

- The costs for the treatment with SUPRA SDRM[®] decreased to the point that patients did not incur on any costs from the 11th week onwards because they were completely healed.
- Cumulative costs showed higher costs in the collagen group after the 6th week.
- By the end of the trial, the total mean costs per patient for the collagen group were almost twice higher than those in the SUPRA SDRM[®] group.

¹ Wounds. 2023 Aug;35(8):E257-E260

* QALY=quality-adjusted life years



PolyMedics Innovations GmbH

Am Hegelesberg 1
73230 Kirchheim unter Teck | Germany

Phone +49 (0)711 719 500-0
Fax +49 (0)711 719 500-10
E-mail info@polymedics.com

Polymedics Innovations Inc.

645 Molly Lane, Suite 100
Woodstock, GA 30189

Phone +1 646 6042771
Fax +1 646 3503129
E-mail info.usa@polymedics.com

Imprint: PolyMedics Innovations GmbH

Am Hegelesberg 1
73230 Kirchheim unter Teck
www.polymedics.com

Design PolyMedics Innovations
CEO Prof. Dr. Heinrich Planck
CEO Christian Planck ■